

**BOARD OF MEDICOLEGAL INVESTIGATIONS  
OFFICE OF THE CHIEF MEDICAL EXAMINER**

Central Office  
901 N. Stonewall  
Oklahoma City, Oklahoma 73117  
(405) 239-7141 Fax (405) 239-2430

Eastern Division  
1115 West 17th  
Tulsa, Oklahoma 74107  
(918) 582-0985 Fax (918) 585-1549

**OFFICE USE ONLY**

Re \_\_\_\_\_ Co \_\_\_\_\_

I hereby certify that this is a true and correct copy of the original document. Valid only when copy bears imprint of the office seal.

By \_\_\_\_\_

Date \_\_\_\_\_

**REPORT OF INVESTIGATION BY MEDICAL EXAMINER**

DECEDENT First-Middle-Last Names (Please avoid use of initials) CAROL FAYE DANIELS	Age 61	Birth Date 10/26/1947	Race BLACK	Sex F
---	-----------	--------------------------	---------------	----------

HOME ADDRESS - No. - Street, City, State  
5201 E WILSHIRE, OKLAHOMA CITY, OK

EXAMINER NOTIFIED BY - NAME - TITLE (AGENCY, INSTITUTION, OR ADDRESS) LT MARY ELROD - ANADARKO PD	DATE 08/23/2009	TIME 19:15
--	--------------------	---------------

INJURED OR BECAME ILL AT (ADDRESS) 305 N 1ST STREET	CITY ANADARKO	COUNTY CADDO	TYPE OF PREMISES CHURCH	DATE 08/23/2009	TIME Unknown
LOCATION OF DEATH 305 N 1ST STREET	CITY ANADARKO	COUNTY CADDO	TYPE OF PREMISES CHURCH	DATE 08/23/2009	TIME 12:09 FOUND
BODY VIEWED BY MEDICAL EXAMINER 901 N STONEWALL AVENUE	CITY OKLAHOMA CITY	COUNTY OKLAHOMA	TYPE OF PREMISES MORGUE	DATE 08/24/2009	TIME 09:53

IF MOTOR VEHICLE ACCIDENT:  DRIVER  PASSENGER  PEDESTRIAN

TYPE OF VEHICLE:  AUTOMOBILE  LIGHT TRUCK  HEAVY TRUCK  BICYCLE  MOTORCYCLE  OTHER: \_\_\_\_\_

DESCRIPTION OF BODY	RIGOR	LIVOR	EXTERNAL OBSERVATION		NOSE	MOUTH	EARS
					BLOOD	OTHER	
EXTERNAL PHYSICAL EXAMINATION	Jaw <input type="checkbox"/> Complete <input type="checkbox"/> Neck <input type="checkbox"/> Absent <input type="checkbox"/> Arms <input type="checkbox"/> Passing <input type="checkbox"/> Legs <input type="checkbox"/> Passed <input type="checkbox"/> Decomposed <input type="checkbox"/>	Color _____ Lateral <input type="checkbox"/> Posterior <input type="checkbox"/> Anterior <input type="checkbox"/> Regional _____	Beard _____ Hair _____ Eyes: Color _____ Mustache _____ Opacities _____ Pupils: R _____ L _____ Body Length _____ Body Weight _____		<input type="checkbox"/>	<input type="checkbox"/>	<input type="checkbox"/>
					<input type="checkbox"/>	<input type="checkbox"/>	<input type="checkbox"/>

Significant observations and injury documentations - (Please use space below)  
SEE AUTOPSY REPORT

Probable Cause of Death:

**MULTIPLE INCISED WOUNDS**

Other Significant Medical Conditions:

**Manner of Death:**

Natural  Accident   
Suicide  Homicide   
Unknown  Pending

**Case disposition:**

Autopsy Yes  No   
Authorized by MEDICAL EXAMINER  
Pathologist COLLIE TRANT M.D.  
Not a medical examiner case

**MEDICAL EXAMINER:**

Name, Address and Telephone No.

CHAI S. CHOI M.D.  
901 N. STONEWALL  
OKLAHOMA CITY, OK 73117

I hereby state that, after receiving notice of the death described herein, I conducted an investigation as to the cause and manner of death, as required by law, and that the facts contained herein regarding such death are true and correct to the best of my knowledge.

*Chai S. Choi, M.D.*

Signature of Medical Examiner

CHAI S. CHOI M.D.

08/27/2009

Date

Computer generated report

**0903376**



Board of Medicolegal Investigations  
**Office of the Chief Medical Examiner**  
 901 N. Stonewall  
 Oklahoma City, Oklahoma 73117  
 (405) 239-7141 Voice  
 (405) 239-2430 Fax

**CERTIFICATION**  
 I hereby certify that this document is a true and correct copy of the original document. Valid only when copy bears imprint of the office seal.  
 By \_\_\_\_\_  
 Date \_\_\_\_\_

**REPORT OF AUTOPSY**

<b>Decedent</b> <b>CAROL FAYE DANIELS</b>	<b>Age</b> <b>61</b>	<b>Birth Date</b> <b>10/26/1947</b>	<b>Race</b> <b>BL</b>	<b>Sex</b> <b>F</b>	<b>Case No</b> <b>0903376</b>
--	-------------------------	--	--------------------------	------------------------	----------------------------------

<b>Type of Death</b> Violent, unusual or unnatural	<b>Means</b>	<b>ID By</b> <b>Toe tag</b>	<b>Authority for Autopsy</b> Collie Trant, M.D.
---	--------------	--------------------------------	--

**Present at Autopsy**  
**Robert Sawyers**

**FINDINGS**

- I. Incised wounds of neck across the high neck
  - A. Incised wound of trachea and front neck muscle
- II. Multiple incised wounds over the chest
- III. Cuts and superficial cuts over the face, chest, abdomen, and right back
- IV. Cuts of both hands (right x6 and left x5)
  - V. Small cutaneous contusion, right arm, and abrasion, left knee
- VI. Truncal obesity
  - A. Fatty metamorphosis of liver, moderate

Comment: The case was reviewed by Chai S. Choi, M.D.

**CAUSE OF DEATH:** MULTIPLE INCISED WOUNDS

**MANNER OF DEATH:** HOMICIDE

The facts stated herein are true and correct to the best of my knowledge and belief.

*Chai S. Choi, M.D.*

OCME Central Division

8/24/2009 9:53 AM

CHAI S. CHOI, M.D.

Pathologist

Location of Autopsy

Date and Time of Autopsy

CME-2

**EXTERNAL EXAMINATION**

DESCRIPTION						
Height	Weight	Eyes	Pupils		Opacities, Etc.	Hair
in.	kg.	Brown	R 5 mm	L 5 mm		
RIGOR (jaw, neck, back, legs, arm, chest, abd., complete)			LIVOR (color, anterior, posterior, lateral, regional)		Body Heat	
Complete			Purple, posterior, fixed		COOL	

**DESCRIPTION OF CLOTHING:**

None.

**MEDICAL APPLICATION:**

None.

**EXTERNAL:**

The body is that of a well developed, apparently obese, black female. The scalp hair is black, 4 inches long, and shows singed hair to the scalp, likely on top of the head. There is blood smearing over most of the right side of the face down to the neck. The conjunctivae are white and show no petechiae. There is ear piercing x1, bilateral. There is no blood in the nose, mouth, or ear canals. The inside of mouth is unremarkable. The neck shows multiple incised wounds which will be described below. The chest shows blood stains over the right breast and the right shoulder and upper chest, along with multiple incised wounds, mainly over the left side of the breast and chest which will be described below. The abdomen is elevated and shows a brownish birth mark over the right epigastrium and a vertical midline laparotomy scar over the lower abdomen. The genitalia are those of normal adult female and are unremarkable. The extremities are symmetric and show both hands being secured with brown paper bags, being sealed. Upon releasing the bags, there are blood stains over both palms and the dorsum of the left hand, including forearms and left arm at the posterior surface. There is a ring with clear stones on the right fourth finger. The stone part of the ring is on the palm side. There are depigmented scars over the legs and knees and a small red abrasion over the left knee. There are multiple cuts of the hands, which will be described below. The back is unremarkable, other than multiple incised wounds over the back of the neck and the back of the right shoulder. There is a suggestive blood stain over the bottom of the left foot (sole). There is dripping blood over the posterolateral surface of the left forearm and the dorsum of the hand.

**EVIDENCE OF INJURY:**

1. Head with three cuts over the left eyebrow, chin, and right cheek (x3) and a superficial cut (x1) over the right lower cheek
2. Neck; horizontal curvilinear gaping incised wounds across the larynx, extending lateral and toward the back of neck
  - A. Six cuts of upper margins, seven cuts of lower margins, two cuts at the right lateral end and six cuts at left lateral end

External exam cont.

- B. Diagonal incised wound over the right back of the neck with 3-4 cuts from the margins
- C. Incised wound of the high neck at the left lateral posterior, cutting left earlobe
- D. Horizontal cut of the thyroid gland/muscle (approximately 5 cm long) and trachea (2.6 cm long)
- 3. Multiple incised wounds of left chest
  - A. Vertical and diagonal complex incised wounds
    - i. Vertical incised wounds (8) and diagonal incised wounds (4)
    - ii. Cuts and superficial cuts (x5) and superficial serrated linear abrasion over the right upper chest
- 4. Two vertical and horizontal cuts over the left epigastrium and the right back and five superficial cuts over the epigastrium and lower abdomen
- 5. Incised wounds of the left hand (x 5~6) with cutting musculature of first web, and right hand (x6). The left hand shows a horizontal deep cut extending to the regional musculature of the first web and two horizontal cuts over the palm, along with diagonal horizontal cuts of the left index finger. The thumb shows a curvilinear cut at the medial surface

Injuries are depicted in CME-1B1, 2, 8, and 9.

## GROSS EXAMINATION

---

The body is opened through the customary “Y” shaped incision.

Subcutaneous fat is excessively distributed with multiple incised wounds over the chest and abdomen described above.

The sternum is removed in the customary fashion. The organs of the chest and abdomen are in normal position and relationship. The diaphragms are intact bilaterally.

### **PARIETAL PLEURA:**

No description.

### **PERICARDIUM:**

No description.

### **PERITONEUM:**

Smooth, glistening membrane in both the abdominal and pelvic cavities. The peritoneal cavity contains no abnormal fluid or adhesions.

### **HEART:**

Weighs 330 gm. It has a normal configuration and location. There are no adhesions between the parietal and visceral pericardium, and the latter is a smooth, glistening, fat laden characteristic membrane. The coronary arteries arise and distribute normally with mild atherosclerosis. The myocardium is unremarkable with the left ventricle measuring 1.2 cm and the right ventricle measuring 0.3 cm.

### **NECK ORGANS:**

Musculature is normal, rubbery, and maroon, and the organs are freely movable in a midline position. The tongue is intact and normally papillated, without evidence of tumor or hemorrhage. The hyoid bone is intact. There is a horizontal cut, 5 cm, across the thyroid gland versus muscle. The epiglottis is a characteristic plate-like structure which shows no evidence of edema, trauma, or other gross pathology. The larynx is comprised of unremarkable vocal cords and folds, is widely patent without foreign material, and is lined by a smooth, glistening membrane. There are no petechiae of the epiglottis, laryngeal mucosa, or thyroid capsule.

**THYMUS:**

No significant tissue is identified grossly.

**LUNGS:**

The lungs show mild anthracosis and is pink. The overall configuration is hyperinflated. The trachea shows a 2.6 cm horizontal cut at the level of 2.5 cm below the vocal cord.

**G.I. TRACT:**

The stomach is of normal configuration, is lined by a smooth, glistening, intact mucosa, has an unremarkable wall and serosa, and contains approximately 50 mL of dark brown partly digested food material that includes ground meat and cheese. The duodenum, itself, is patent, shows an unremarkable mucosa and no evidence of acute or chronic ulceration. Jejunum and ileum are unremarkable and contain soft brown fecal material. There is no Meckel's diverticulum. The ileocecal valve is intact and unremarkable. The appendix is present.

**LIVER:**

Weighs 2110 gm and is yellowish and fatty.

**GALLBLADDER:**

Lies in its usual position, contains liquid bile, no calculi, and shows an unremarkable mucosa. The biliary tree is intact and patent without evidence of neoplasm or calculi.

**PANCREAS:**

Lies in its normal position and is unremarkable.

**SPLEEN:**

Weighs 140 gm. The capsule is intact.

**ADRENALS:**

Lie in their usual location, show yellow cortices and tan to gray medullae.

**KIDNEYS:**

The right kidney weighs 130 gm and the left weighs 150 gm

**URINARY BLADDER:**

Contains no urine.

**FEMALE GENITALIA:**

Previous hysterectomy, remote.

**BRAIN AND MENINGES:**

The scalp is opened through the customary intermastoid incision and shows no trauma. The calvarium is removed through the use of an oscillating saw and is intact without evidence of osseous disease. The brain weighs 1150 gm. Dura and leptomeninges are smooth, glistening, translucent, and unremarkable without evidence of trauma. Cranial nerves and circle of Willis arise and distribute normally and show no significant pathology. Externally the brain is normally configured and symmetric, and multiple serial sections of cerebral hemispheres, pons, medulla, and cerebellum are unremarkable. The base of the skull is intact without osseous abnormality.

**RIBS:**

Intact.

**PELVIS:**

Intact.

**VERTEBRAE:**

Intact.

**BONE MARROW:**

Unremarkable.

**MICROSCOPIC EXAMINATION**

---

Heart section shows no significant pathology, other than rare hypertrophic myocardial fibers. There is no evidence of hemorrhages.

Liver section shows moderate fatty metamorphosis of hepatocytes in the centrilobular zone and unremarkable portal space.

Kidney section shows unremarkable glomeruli and tubules that are partly autolytic.


Spleen section shows partly autolytic tissue with a suggestion of sinus opening. Lymphocytic cells are somewhat depleted with no evidence of germinal centers.

Pancreatic tissue is autolytic, being otherwise unremarkable.

Sections of lungs show focal granuloma with multinucleated giant cells and lymphocytic cells infiltration. Overall lung tissue is unremarkable with a focal suggestion of aspiration in the bronchus.

Sections from thyroidal region show focal acute hemorrhage.

April 01, 2010  
CSC/lv



---

CHAI S. CHOI, M.D.

**BOARD OF MEDICOLEGAL INVESTIGATIONS  
OFFICE OF THE CHIEF MEDICAL EXAMINER**

901 N.Stonewall  
Oklahoma City, Oklahoma 73117

**REPORT OF LABORATORY ANALYSIS**

OFFICE USE ONLY

Re. \_\_\_\_\_ Co. \_\_\_\_\_

I hereby certify that this is a true and correct copy of the original document. Valid only when copy bear im-print by the office seal.

By \_\_\_\_\_

Date \_\_\_\_\_

ME CASE NUMBER: 0903376

LABORATORY NUMBER: 093221

DECEDENT'S NAME: CAROL FAYE DANIELS

DATE RECEIVED: 08/27/2009

MATERIAL SUBMITTED: BLOOD, VITREOUS, BILE

HOLD STATUS: 5 YEARS

SUBMITTED BY: ROBERT SAWYERS

MEDICAL EXAMINER: COLLIE TRANT M.D.

**NOTES:**

**ETHYL ALCOHOL:**

Blood: NEGATIVE (HEART)

Vitreous:

Other:

**CARBON MONOXIDE**

Blood:

**TESTS PERFORMED:**

BLOOD BASES

BLOOD EIA - Amphetamine, Methamphetamine, Cocaine, Opiates\*, PCP, Barbiturates, Benzodiazepines, Fentanyl\*

\* This test does not detect Oxycodone, Methadone, Lorazepam, Nitrobenzodiazepines.

BLOOD VOLATILES

**RESULTS:**

NONE DETECTED

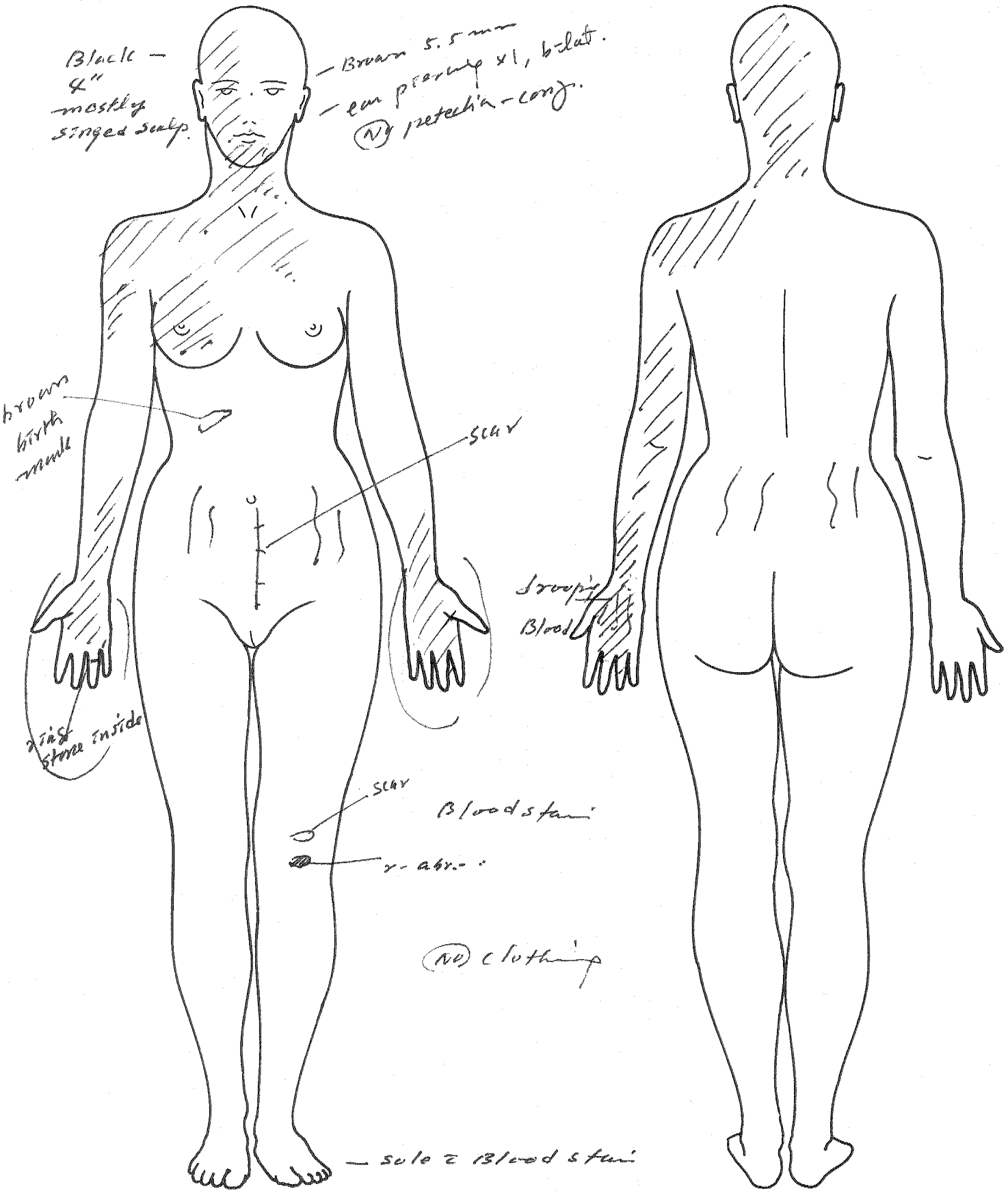
10/22/2009

DATE



BYRON CURTIS, Ph.D., Chief Forensic Toxicologist

FULL BODY, FEMALE - ANTERIOR AND POSTERIOR VIEWS

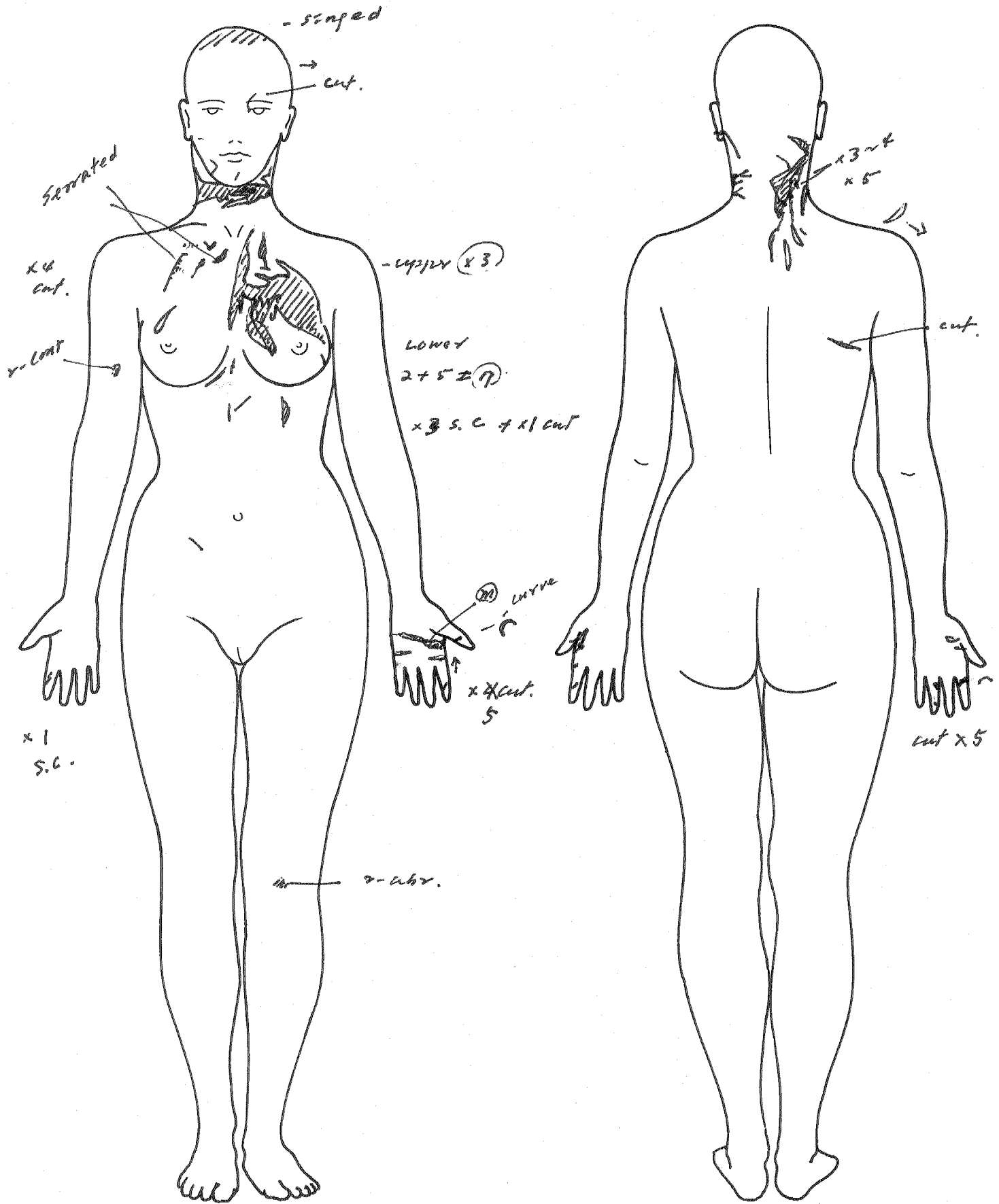


Name Carolyn Daniels

Case No. 0903376

Date 3-29-2010

FULL BODY, FEMALE - ANTERIOR AND POSTERIOR VIEWS

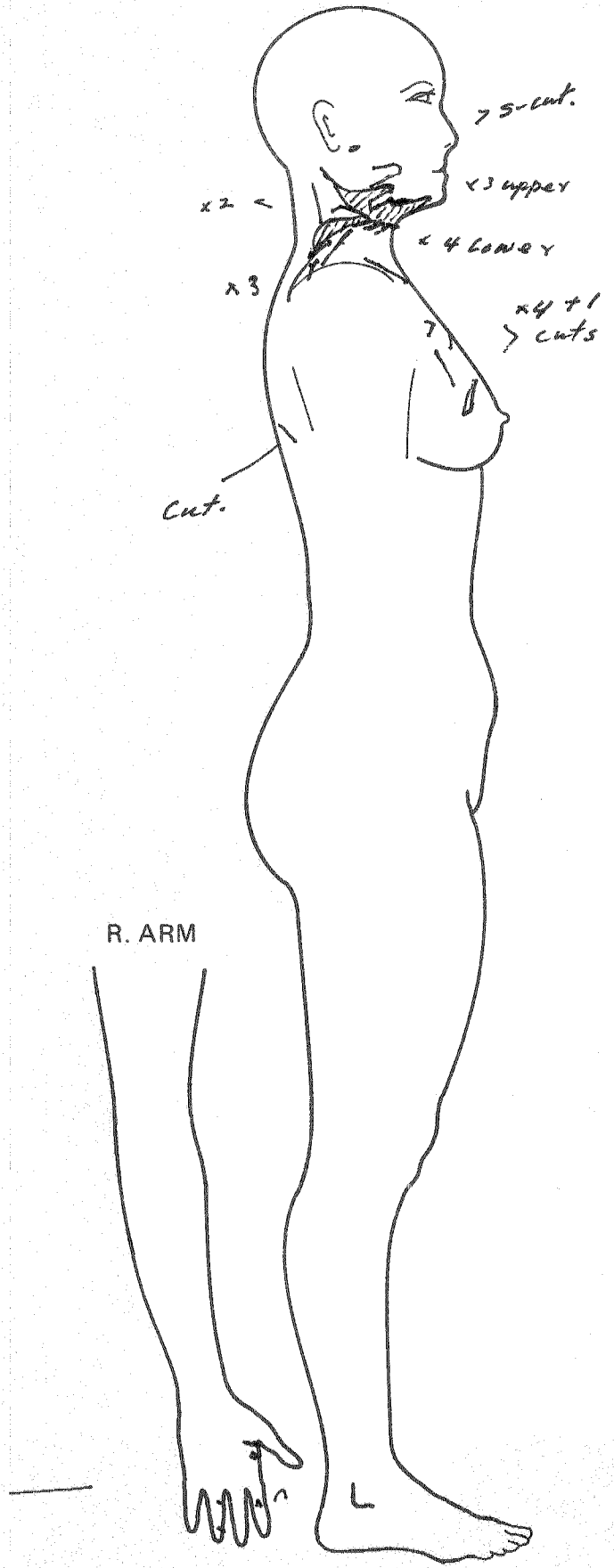
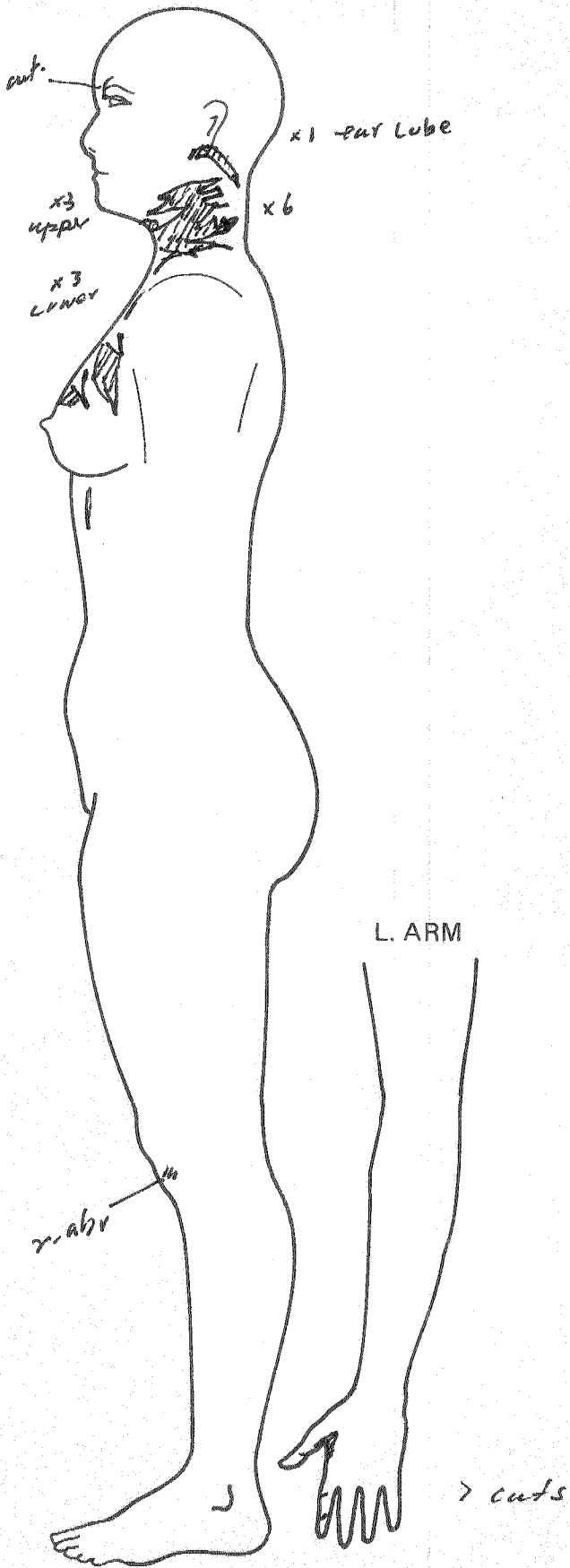


Name Carolyn Daniels

Case No. 0903376

Date 3-29-2010

FULL BODY, FEMALE - LATERAL VIEW

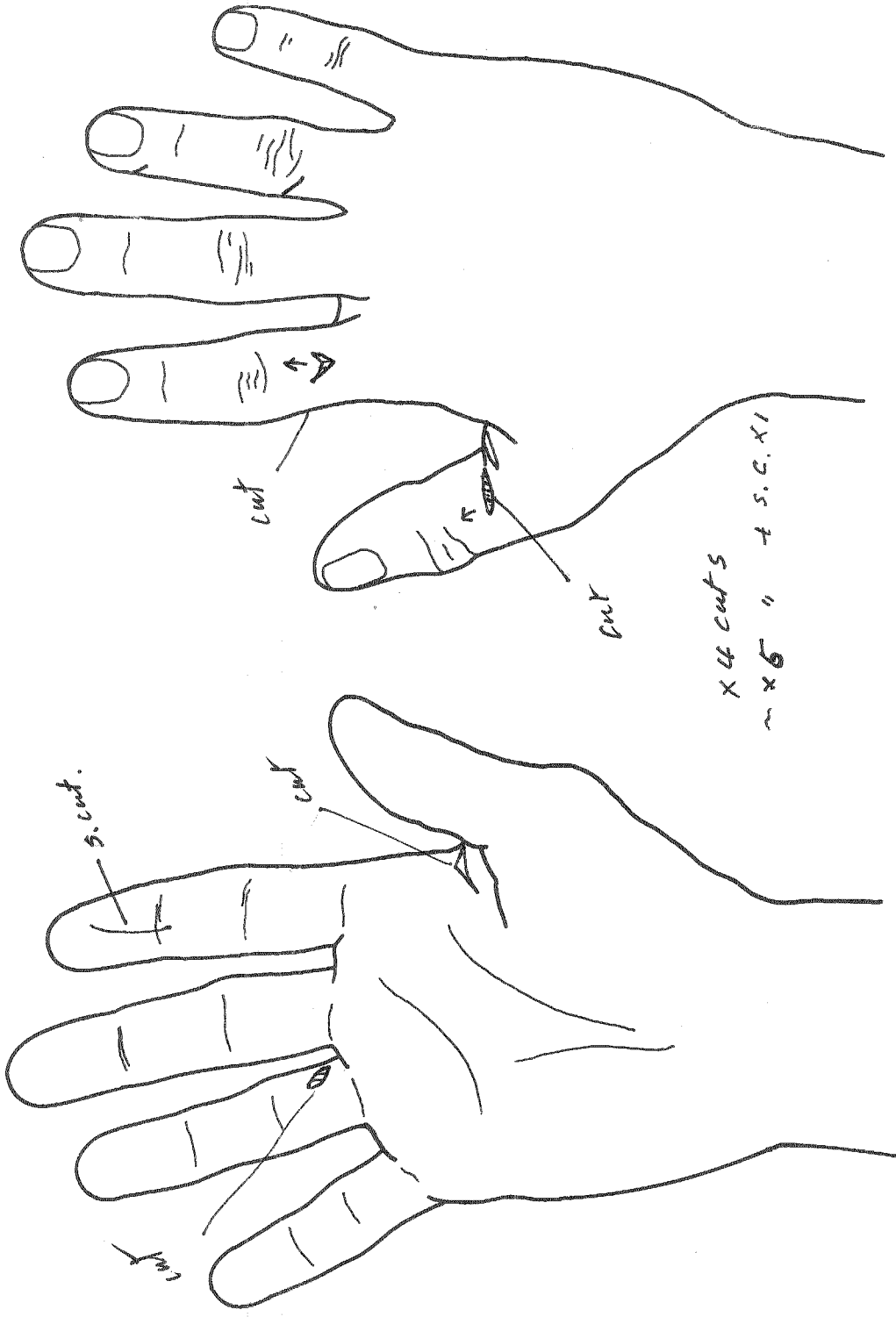


Name Carolyn Daniels

Case No. 0903376

Date 3-29-2010

RIGHT HAND - PALMAR AND DORSAL

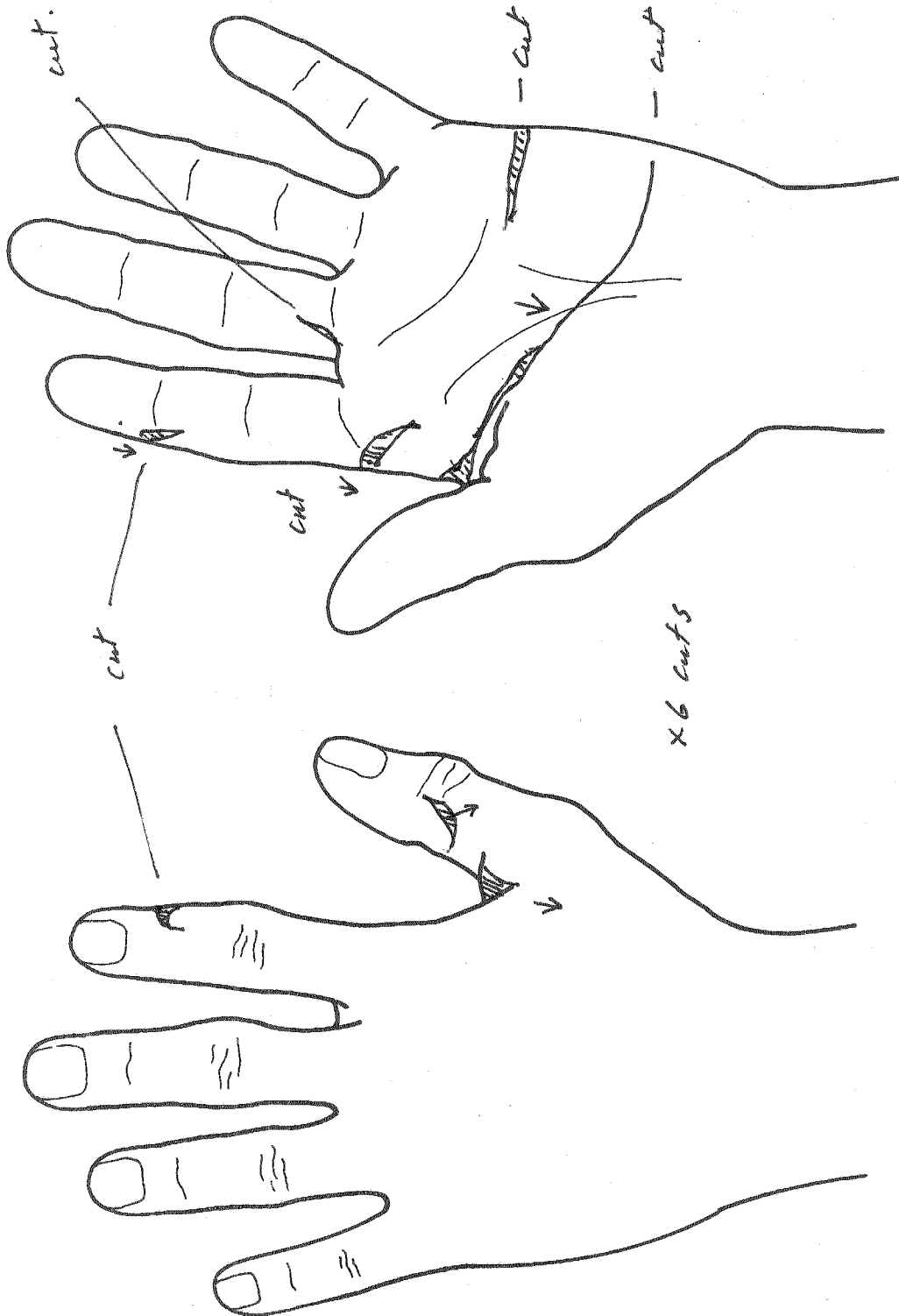


Name Carolyn Daniels

Case No. 0903376

Date 3-29-2010

LEFT HAND -- PALMAR AND DORSAL



Name Carolyn Daniels

Case No. 0903376

CME-1B9 (Series 1978)

Date 3-29-2010